

**Wound, Ostomy and
Continence Nurses Society's
Guidance on OASIS-C1
Integumentary Items:
Best Practice for Clinicians**



Wound
Ostomy and
Continence
Nurses
Society®

Acknowledgments

Wound, Ostomy and Continence Nurses Society's Guidance on OASIS-C1 Integumentary Items:
Best Practice for Clinicians

*This document was developed by the WOCN Society's OASIS Task Force
between August 2013 - January 2014.*

Ben Peirce, Chair, RN, CWOCN
National Specialist, Clinical Practice and Outcomes
*Gentiva Home Care and Hospice
Ft. Lauderdale, Florida*

Barbara Dale, BSN, RN, CWOCN, CHHN
Director of Wound Care
*Quality Home Health
Livingston, Tennessee*

Dianne Mackey, MSN, RN, CWOCN
Wound/Skin Coordinator
*Kaiser Permanente Home Health Department
San Diego, California*

Laurie McNichol, MSN, RN, GNP, CWOCN, CWON-AP
Clinical Nurse Specialist/WOC Nurse
*Cone Health
Greensboro, North Carolina*

Copyright© 2014 by the Wound, Ostomy and Continence Nurses Society™. Date of Publication:
2/28/2014. No part of this publication may be reproduced, photocopied, or republished in any form, in
whole or in part, without written permission of the Wound, Ostomy and Continence Nurses Society.

Overview and Background

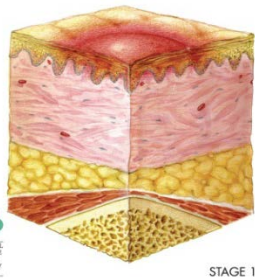
OASIS-C1 is a modification to the Outcome and Assessment Information Set (OASIS) that Home Health Agencies must collect in order to participate in the Medicare program. This is the second update of the OASIS since it was implemented in 2000.

This update includes changes to prepare for ICD-10 implementation in 2014. The system for wound classification uses terms that lack universal definition and clinicians have verbalized concerns that they may be interpreting these terms incorrectly. The WOCN[®] Society has therefore developed the following guidelines for the classification of wounds. These items were developed by consensus among the WOCN Society panel of content experts.

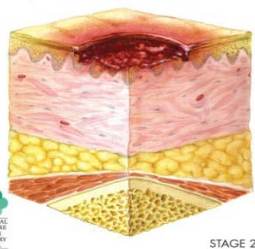
- (M1300) **Pressure Ulcer Assessment:** Was this patient assessed for **Risk of Developing Pressure Ulcers**?
- (M1302) Does this patient have a Risk of **Developing Pressure Ulcers**?
- (M1306) Does this patient have at least one **Unhealed Pressure Ulcer at Stage II or Higher** or designated as “unstageable”?

Definitions.

- **Unhealed:**
 - The absence of the skin’s original integrity.
- **Non-epithelialized:**
 - The absence of the regeneration of the epidermis across a wound surface.
- **Pressure Ulcer:**
 - *A pressure ulcer is localized injury to the skin and/or underlying tissue, usually over a bony prominence, as a result of pressure or pressure in combination with shear. A number of contributing or confounding factors also are associated with pressure ulcers; the significance of these factors is yet to be elucidated.*
- **Pressure Ulcer Stages (NPUAP):**

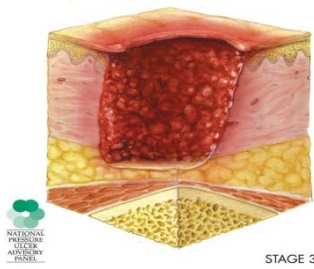


Category/Stage I: Non-blanchable erythema. A Stage I pressure ulcer presents as intact skin with non-blanchable redness of a localized area, usually over a bony prominence. Darkly pigmented skin may not have visible blanching; its color may differ from the surrounding area. The area may be painful, firm, soft, and warmer or cooler as compared to adjacent tissue. Stage I ulcers may be difficult to detect in individuals with dark skin tones and may indicate “at risk” persons (a heralding sign of risk).

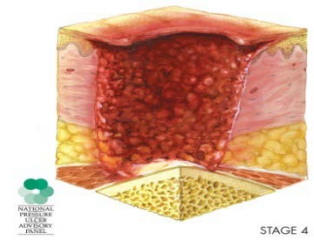


Category/Stage II: Partial thickness. A Stage II pressure ulcer is characterized by partial-thickness loss of dermis presenting as a shallow open ulcer with a red-pink wound bed without slough. It also may present as an intact or open/ruptured serum-filled blister. A Stage II ulcer also may present as a shiny or dry shallow ulcer without slough or bruising.* This stage should not be used to describe skin tears, tape burns, perineal dermatitis, maceration, or excoriation.

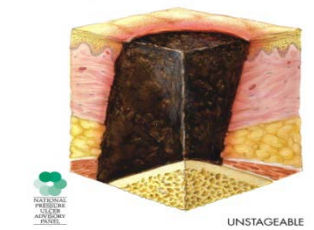
*Bruising indicates suspected deep tissue injury.



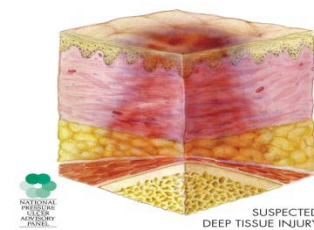
Category/Stage III: Full thickness skin loss. A Stage III pressure ulcer is characterized by full-thickness tissue loss. Subcutaneous fat may be visible but bone, tendon, or muscle is not exposed. Slough may be present but does not obscure the depth of tissue loss. Stage III ulcers may include undermining and tunneling. The depth of a Stage III pressure ulcer varies by anatomical location. The bridge of the nose, ear, occiput, and malleolus do not have subcutaneous tissue; Stage III ulcers in these locations can be shallow. In contrast, areas of significant adiposity can develop extremely deep Stage III pressure ulcers. Bone/tendon is not visible or directly palpable.



Category/Stage IV: Full thickness tissue loss. A Stage IV pressure ulcer presents with full-thickness tissue loss with exposed bone, tendon, or muscle. Slough or eschar may be present on some parts of the wound bed. These ulcers often include undermining and tunneling. The depth of a Stage IV pressure ulcer varies by anatomical location. The bridge of the nose, ear, occiput, and malleolus do not have subcutaneous tissue; Stage IV ulcers in these locations can be shallow. Stage IV ulcers can extend into muscle and/or supporting structures (e.g., fascia, tendon, or joint capsule); osteomyelitis is possible. Exposed bone/tendon is visible or directly palpable.



Unstageable/Unclassified: Full thickness skin or tissue loss – depth unknown. Full-thickness tissue loss in which the base of the ulcer is covered by slough (yellow, tan, gray, green or brown) and/or eschar (tan, brown or black) in the wound bed may render a wound unstageable. Until enough slough and/or eschar is removed to expose the base of the wound, the true depth (and therefore, the stage) cannot be determined. Stable (dry, adherent, intact without erythema or fluctuance) eschar on the heels serves as “the body’s natural (biological) cover” and should not be removed.



Suspected Deep Tissue Injury – depth unknown. Deep tissue injury may be characterized by a purple or maroon localized area of discolored intact skin or a blood-filled blister due to damage of underlying soft tissue from pressure and/or shear. Presentation may be preceded by tissue that is painful, firm, mushy, boggy, and warmer or cooler as compared to adjacent tissue. Deep tissue injury may be difficult to detect in individuals with dark skin tones. Evolution may include a thin blister over a dark wound bed. The wound may further evolve and become covered by thin eschar. Evolution may be rapid, exposing additional layers of tissue even with optimal treatment.

- (M1307) The **Oldest Stage II Pressure Ulcer** that is present at discharge.
- (M1308) **Current Number of Unhealed Pressure Ulcers at Each Stage or Unstageable.**
- (M1309) **Worsening in Pressure Ulcer Status since SOC/ROC.**

- (M1320) **Status of Most Problematic Pressure Ulcer that is Observable:**
0 – Newly epithelialized
1 – Fully granulating
2 – Early/partial granulation
3 – Not healing
NA – No observable pressure ulcer

Definitions.

- **Newly epithelialized:**
 - Wound bed completely covered with new epithelium.
 - No exudate.
 - No avascular tissue (eschar and/or slough).
 - No signs or symptoms of infection.
- **Fully granulating:**
 - Wound bed filled with granulation tissue to the level of the surrounding skin.
 - No dead space.
 - No avascular tissue (eschar and/or slough).
 - No signs or symptoms of infection.
 - Wound edges are open.
- **Early/partial granulation:**
 - $\geq 25\%$ of the wound bed is covered with granulation tissue.
 - $< 25\%$ of the wound bed is covered with avascular tissue (eschar and/or slough).
 - No signs or symptoms of infection.
 - Wound edges open.
- **Not healing:**
 - Wound with $\geq 25\%$ avascular tissue (eschar and/or slough) OR
 - Signs/symptoms of infection OR
 - Clean but non-granulating wound bed OR
 - Closed/hyperkeratotic wound edges OR
 - Persistent failure to improve despite appropriate comprehensive wound management.

- (M1322) **Current Number of Stage I Pressure Ulcers.**
(M1324) **Stage of Most Problematic Unhealed Pressure Ulcer that is Stageable.**
(M1330) **Does this patient have a Stasis Ulcer?**
(M1332) **Current Number of Stasis Ulcer(s) that are Observable.**
(M1334) **Status of Most Problematic Stasis Ulcer that is Observable:**
1 – Fully granulating
2 – Early/partial granulation
3 – Not healing

Definitions.

- **Fully granulating**
 - Wound bed filled with granulation tissue to the level of the surrounding skin.
 - No dead space.
 - No avascular tissue (eschar and/or slough).
 - No signs or symptoms of infection.
 - Wound edges are open.
- **Early/partial granulation**
 - $\geq 25\%$ of the wound bed is covered with granulation tissue.
 - $< 25\%$ of the wound bed is covered with avascular tissue (eschar and/or slough).
 - No signs or symptoms of infection.
 - Wound edges open.
- **Not healing**
 - Wound with $\geq 25\%$ avascular tissue (eschar and/or slough) OR
 - Signs/symptoms of infection OR
 - Clean but non-granulating wound bed OR
 - Closed/hyperkeratotic wound edges OR
 - Persistent failure to improve despite appropriate comprehensive wound management.

(M1340) Does this patient have a **Surgical Wound?**

(M1342) **Status of Most Problematic Surgical Wound that is Observable:**

- 0 – Newly epithelialized**
- 1 – Fully granulating**
- 2 – Early/partial granulation**
- 3 – Not healing**

Definitions.

- **Newly epithelialized**
 - Wound bed completely covered with new epithelium.
 - No exudate.
 - No avascular tissue (eschar and/or slough).
 - No signs or symptoms of infection.
- **Fully granulating**
 - Wound bed filled with granulation tissue to the level of the surrounding skin.
 - No dead space.
 - No avascular tissue (eschar and/or slough).
 - No signs or symptoms of infection.
 - Wound edges are open.
- **Early/partial granulation**
 - $\geq 25\%$ of the wound bed is covered with granulation tissue.
 - $< 25\%$ of the wound bed is covered with avascular tissue (eschar and/or slough).
 - No signs or symptoms of infection.
 - Wound edges open.

- **Not healing**
 - Wound with $\geq 25\%$ avascular tissue (eschar and/or slough) OR
 - Signs/symptoms of infection OR
 - Clean but non-granulating wound bed OR
 - Closed/hyperkeratotic wound edges OR
 - Persistent failure to improve despite appropriate comprehensive wound management.

This guidance applies to surgical wounds closed by either primary intention (specifically, approximated incisions) or secondary intention (specifically, open surgical wounds).

(M1350) Does this patient have a **Skin Lesion** or **Open Wound** (excluding bowel ostomy), other than those described above, that is receiving intervention by the home health agency?

Glossary

Avascular:	Lacking in blood supply; synonyms are dead, devitalized, necrotic, and nonviable. Specific types include slough and eschar.
Clean Wound:	Wound free of devitalized tissue, purulent drainage, foreign material or debris.
Closed Wound Edges:	Edges of top layers of epidermis have rolled down to cover lower edge of epidermis, including basement membrane, so that epithelial cells cannot migrate from wound edges; also described as epibole. Presents clinically as sealed edge of mature epithelium; may be hard/thickened; may be discolored (for example, yellowish, gray, or white).
Dead Space:	A defect or cavity.
Dehiscence/Dehiscence:	Separation of surgical incision; loss of approximation of wound edges.
Epidermis:	Outermost layer of skin.
Epithelialization:	Regeneration of epidermis across a wound surface.
Eschar:	Black or brown necrotic, devitalized tissue; tissue can be loose or firmly adherent, hard, soft or soggy.
Full Thickness:	Tissue damage involving total loss of epidermis and dermis and extending into the subcutaneous tissue and possibly into the muscle or bone.
Granulation Tissue:	The pink/red, moist tissue comprised of new blood vessels, connective tissue, fibroblasts, and inflammatory cells, which fills an open wound when it starts to heal; typically appears deep pink or red with an irregular, “berry-like” surface.
Healing:	A dynamic process involving synthesis of new tissue for repair of skin and soft tissue defects.
Hyperkeratosis:	Hard, white/gray tissue surrounding the wound.

Infection:	The presence of bacteria or other microorganisms in sufficient quantity to damage tissue or impair healing. Wounds can be classified as infected when the wound tissue contains 100,000 or greater microorganisms per gram of tissue. Typical signs and symptoms of infection include purulent exudate, odor, erythema, induration, warmth, tenderness, edema, pain, fever, and elevated white cell count. However, clinical signs of infection may not be present, especially in the immunocompromised patient or the patient with poor perfusion.
Necrotic Tissue:	See avascular.
Newly Epithelialized:	The process of regeneration of the epidermis across a wound surface or regeneration of the epidermis across a wound surface.
Non-epithelialized:	Absence of the regeneration of the epidermis across a wound surface.
Non-granulating:	Absence of granulation tissue; wound surface appears smooth as opposed to granular. For example, in a wound that is clean but non-granulating, the wound surface appears smooth and red or pink as opposed to berry-like.
Partial Thickness:	Confined to the skin layers; damage does not penetrate below the dermis and may be limited to the epidermal layers only.
Scab:	A crust of dried blood or serum.
Sinus Tract:	Course or path of tissue destruction occurring in any direction from the surface or edge of the wound; results in dead space with potential for abscess formation. Also sometimes called “tunneling.” (Can be distinguished from undermining by fact that sinus tract involves a small portion of the wound edge whereas undermining involves a significant portion of the wound edge.)
Slough:	Soft moist avascular (devitalized) tissue; may be white, yellow, tan, or green; may be loose or firmly adherent.
Stage IV Structures:	Anatomical structures, any of which when visible in a full thickness pressure ulcer indicate the wound is reportable as a Stage IV pressure ulcer. Stage IV structures include bone, muscle, tendon, ligament, and joint capsule.
Tunneling:	See sinus tract.

Undermining:

Area of tissue destruction extending under intact skin along the periphery of a wound; commonly seen in shear injuries. Can be distinguished from sinus tract by fact that undermining involves a significant portion of the wound edge, whereas sinus tract involves only a small portion of the wound edge.

Unhealed:

Absence of the skin's original integrity.



Wound
Ostomy and
Continence
Nurses
Society®

Wound, Ostomy and Continence Nurses Society

www.wocn.org

888-224-9626, toll-free

This document was developed by the WOCN Society's OASIS Task Force.